

Manipulation of the spine and appendages under anesthesia: An evaluation

IRA C. RUMNEY, D.O., F.A.A.O.
Kirksville, Missouri

Manipulative therapy to the musculoskeletal system under anesthesia has a definite place as an elective modality. The success of the procedure is directly related to the physician's manipulative skill. The selection of patients requires a thorough understanding of the underlying pathologic condition and how it led to the present problem. Conditions that respond well to the procedure include chronic myositis, nerve entrapment, chronic fibrositis, anomalies with restricted motion after trauma, chronic muscle contracture, and, occasionally, acute muscle spasm associated with subluxation. Manipulation under anesthesia is contraindicated in malignancy with metastasis to bone, fracture, acute arthritis, tuberculosis of the bone, acute gout, and uncontrolled diabetic neuropathy. The procedure must be carried out in a hospital setting.

Manipulation of the joints of the spine and the appendages under anesthesia has been carried out by orthopedic surgeons for many years, in both the osteopathic and allopathic professions. Also, many osteopathic physicians who are not orthopedic surgeons have found it advantageous in selected cases to use gen-

eral anesthesia when applying manipulative therapy to the spine and/or the appendages. As one reviews the osteopathic and allopathic literature, it appears that the degree of skill in using this particular type of therapy is highest among the osteopathic physicians and the European allopathic physicians.

To acquire a greater background knowledge from which to write this paper, I talked with many osteopathic physicians who are applying manipulative therapy to the spine and appendages under anesthesia for special conditions, and I have also observed several osteopathic physicians as they employed this type of therapy in hospitals in the East and Midwest.

There is a definite place for manipulative therapy to the musculoskeletal system under anesthesia. The greater one's skill in applying manipulative therapy to problems of the musculoskeletal system, the less often will it be necessary to use anesthesia to get the desired results. By the same token, the greater one's skill in manipulative therapy, the better the results obtained when such treatment must be done under anesthesia. It is interesting to find that Wiles and Sweetnam,¹ in discussing the treatment of backache, make a similar comment:

Manipulation is an important feature of the active treatment of both acute and chronic back pain An anaesthetic may be desirable when there is severe pain and spasm—the need for anaesthesia varies inversely with the skill of the surgeon.

Indications and contraindications

The indications for manipulative procedures under general anesthesia are primarily conditions in which manipulation is the therapy of choice, but which do not respond satisfactorily to manipulation without anesthesia.

Conditions that respond well to manipulation of the musculoskeletal system under

anesthesia are nerve entrapment, chronic myositis, chronic fibrositis, anomalies with restricted motion following trauma, chronic muscle contracture, and, occasionally, acute muscle spasm associated with subluxation. These disorders may involve the spine, particularly the cervical or lumbar spine, knee, ankle, patella, shoulder, et cetera.

The duration of conservative manipulative therapy without anesthesia may vary from 1 day to 6 weeks. Conditions that at times may need immediate manipulation under anesthesia are the acute knee injury, acute low-back strain, and injuries to the neck received in automobile accidents, frequently referred to as "whiplash injury." Tospon² reports that, in treating over 200 cases of ligamentous strain of the neck due to auto accident, early manipulation under anesthesia (second or third week after the accident) lessened the morbidity and hastened the recovery.

More than 15 years ago, Siehl and Bradford³ reported on their use of manipulative therapy under anesthesia on patients with low-back problems, and in 1963 Siehl⁴ published his further experience with the technique. He is now using manipulative therapy under anesthesia on all patients with disk problems before attempting surgical correction.⁵ Many of the patients become symptom free and do not require surgery. He is doing electromyographic studies and clinical neurologic examinations on all patients before and after using manipulative therapy under anesthesia, and is finding electromyographic and clinical evidence of improvement. A nerve root pressure lesion will produce fibrillation potentials at rest in a reasonable number of skeletal muscles which share the damaged nerve root as part of their innervation.

Others have reported good results in low-back problems associated with intervertebral

disk pathology. In 1955 Mensor⁶ reported good results in 64 per cent of private practice patients and 45 per cent of patients whose disability was caused by industrial accidents. After 20 years' experience and treatment of more than 600 patients with manipulation of the back under anesthesia he has had sufficiently satisfactory results to continue with this procedure.

The conditions that one may treat for periods ranging from a few days to 6 weeks before attempting manipulation under anesthesia are the frozen shoulder, chronic capsulitis, low-back strain, old sacroiliac strain, and old traumatic joint injuries. Some orthopedic surgeons recommend that conservative physiotherapy be used as long as 6 months before surgery is done for the disk syndrome.

The contraindications to manipulation under anesthesia are malignancy with metastasis to bone, tuberculosis of the bone, fractures, acute arthritis, acute gout, uncontrolled diabetic neuropathy, and neuropathies from other causes.

Osteoporosis of itself may or may not be a contraindication to manipulation under anesthesia, depending on whether the condition is the result of a metabolic process, as is the osteoporosis occasionally associated with the menopause, or whether it is an osteoporotic process secondary to disuse. Manipulation can be advantageous in many of these conditions providing the extent of the osteoporosis is known and the manipulative forces are gauged accordingly. If one can re-establish the use of the part, the osteoporosis will be ameliorated. Joints with restricted motion that are related to segments of the spinal cord from which are derived nerves manifesting neuropathic symptoms can also be manipulated with resultant lessening of symptoms.

Manipulation of the musculoskeletal system

under anesthesia is not looked upon favorably by some physicians. It seems that there are three reasons for this: (1) The person knows nothing about the procedure and thinks it is something done by "unqualified individuals."

(2) Numerous physicians have used very crude techniques which were not specifically applied for the particular problem, but consisted only of a general "popping" of the joints, with the result that mobility in the already mobile joints was increased and those that really needed to be mobilized were left as they were. At times the manipulative procedure was traumatic and not therapeutic.

(3) Anesthesia has been used not because the physician could not have mobilized the joints without it, but because he felt that using anesthesia for the procedure made a greater impression on the patient than simply manipulating the spine as an office procedure.

In selecting patients for manipulation under anesthesia, one must have a thorough understanding of the underlying pathologic condition and how it has led to the present problem. A very careful and detailed history and physical examination are therefore necessary, as well as adequate laboratory procedures, for accurate diagnosis and differential diagnosis. Too many times one forgets that the pathologic changes in joint dysfunction are like those in any other pathologic condition: initially there is intra-articular or periarticular irritation with muscle spasm. The muscle spasm and the irritation lead to inflammation, edema, and fibrous reaction, and the fibrous reaction leads to limited mobility. It is much easier to reverse the process in the stage of inflammation and edema than it is after fibrosis has occurred. When the condition advances to fibrosis one is faced with a prolonged program, and it is at this point that manipulative therapy under anesthesia is most frequently indi-

cated. Even after the manipulative procedures break up the fibrosis, one must institute an adequate program of physical therapy and exercise. Such a program is necessary for sufficient circulation and mobility to prevent the reformation of fibrous tissue. If one does not prevent, or lessen, the formation of fibrous tissue, the patient's original problem will recur. The pathology of the osteopathic lesion has been described by Burns and her associates.⁸

Evaluation of the patient

History

The history should start with the age, height, and weight of the individual; then the chief complaint should be recorded, with its detailed history: where the pain is located and if it radiates, whether the pain came on suddenly or insidiously, and whether any similar condition has occurred in the past. Careful questioning should determine whether any family member has ever had similar complaints. One needs to know whether the patient's pain is increased or decreased by activity. The pain due to trauma is increased by activity, while that caused by arthritis is usually decreased temporarily by activity, and then intensifies. Localized pain suggests fractures, malignancies, or infections; whereas generalized pain may represent an arthritic or a metabolic disturbance. One also needs to know the types of therapy being used at this time or in the past, and their results. Not only should one know the type of therapy that was given but one should also know how it was given, by whom, and where. This information will provide clues as to how adequately the patient's problem may have been evaluated previously as well as an idea of the severity of the condition. It is helpful to know whether or not compensation insurance may be playing a role in the pa-

tient's problem.

The history must include a record of all past illnesses and/or infections, surgical procedures, type of work, athletic participation, weight changes, marital status, and, in the female patient, the number of pregnancies and the physical problems associated with them.

Physical examination

The physical examination starts with inspection. The patient should disrobe, and put on an examining gown. The type that can be opened in the back can be used. The patient should then remove his shoes and stockings. While doing so, he should be observed because this particular procedure requires a certain amount of mobility of the joints of the extremities, and of the low back and pelvis. The use of reflected light in examination of the patient will help one note shadows which may bring out various abnormalities, such as increase or decrease of the anteroposterior curves of the spine, any lateral curves of the spine, or any increase or decrease in muscle mass at any place.

The next phase of inspection consists of watching the patient as he walks, sits down and gets up from a chair, and, if his condition permits, lies down on an examining table and then gets up. The patient should be asked to describe any discomfort experienced in carrying out these procedures.

Next the examiner goes to the gross evaluation of the movements of the joints of the extremities, pelvis, and spine, first observing what the patient can do voluntarily or actively and then noting what passive motions can be carried out. The results of each of these procedures should be carefully recorded. I have described the gross evaluation of the spine in a previous article.⁹

Any area which on gross examination has shown altered range of motion or caused symptoms is then examined in detail, as well as the particular area of complaint. In the detailed search for osteopathic lesions, the examiner looks for hyperalgesia at each joint. He looks at and palpates the skin for manifestations of functional changes of the sympathetic nervous system, such as edema, changes in tissue texture, increase or decrease of moisture on the skin, temperature changes, et cetera. Then he checks for restricted motion by attempting to take each joint through its normal motions, not only the motions under voluntary control but also those not under voluntary control. If an osteopathic lesion is present, the joint will move in the direction in which dysfunction occurred more readily than in the direction necessary for normal motion. By carefully checking the joint, one can determine exactly in what phase of a simple motion or compound motion the restriction occurs. (Restriction rarely occurs in a simple motion.) Then one can apply manipulative procedures to normalize the restricted motion component on the basis of definite knowledge rather than indiscriminately.

When palpating tissues, the examiner needs to check for changes in muscles and fascia, such as contracture or lack of tone, which could lead to altered motion and altered body mechanics. In some joints hypermobility compensates for hypomobility of other joints. This alteration in mobility creates symptoms such as pain, facilitation, dysfunction, somaticovisceral reflex, et cetera. The abnormal proprioceptive impulses fed into the central nervous system produce what Korr¹⁰ has referred to as the "facilitated segment."

Laboratory examination

When the physical examination has been com-

pleted and the findings have been recorded, one is ready to write orders for laboratory examinations, which should include a complete blood count, sedimentation rate, thyroid function tests, urinalysis, and blood uric acid, creatinine, blood sugar, RA latex, C-reactive protein antiserum agglutination, and electrophoretic serum protein determinations. If the patient is a female past 35 years of age, a Papanicolaou smear should be done. If the patient is a male past 40 years of age, serum alkaline and acid phosphatase determinations should be done. After completion of the preliminary work, other laboratory procedures such as isotope scanning, et cetera may be indicated.

Radiologic examination

The minimum x-rays should be anteroposterior and lateral views of the joints involved (the spine, pelvis, or extremities) with right and left oblique studies of the lumbar and thoracic spine, and flexion and extension and oblique studies of the cervical spine. The anteroposterior and lateral studies of the lumbar spine and pelvis should be done with the patient standing. Any difference in leg length will thus be apparent. Many times one will want detailed studies of the joints which are to be manipulated under anesthesia. Motion studies on video tape or cineradiography, may be helpful. One should repeat the x-ray studies 24 to 48 hours after manipulation under anesthesia to see what changes have been brought about by the manipulative procedures.

Preoperative preparation

When the need for manipulation under anesthesia has been determined, the patient should be hospitalized. This procedure should never be attempted in the office. On admission the patient should be prepared as he would be for any elective surgical procedure. The pre-

anesthetic preparation should be done by the anesthesiologist.

When the patient is taken to surgery an intravenous catheter is placed in his arm and taped in place. An intravenous infusion is used to keep the vein open for the anesthetic agent, which in most anesthesiologic practice is Thiopental. While the amount of the agent used depends on the patient and on the time required for the manipulative procedure, it is usually about 20 cc. This is given as needed and the patient's respiratory efforts are kept intact. Oxygen is given by mask as indicated.

Sometimes the procedure will require greater relaxation, necessitating the use of a muscle relaxant. In such instances intubation must be performed to keep the airway patent and thereby insure adequate ventilation during the procedure. Succinylcholine chloride is the relaxant usually used. If the patient is not adequately anesthetized, laryngeal spasm may occur when mobilizing forces are applied in the upper thoracic or lumbosacral areas.

Some operators like to give the patient 5,000 units of ascorbic acid, divided into three doses, daily for approximately 1 week before treating him under anesthesia. Advocates of this therapy feel that it improves adrenal function and helps the body resist any existing infection. The formation of fibrous tissue after the manipulative procedure may thereby be reduced.

Manipulative procedures

In the office practice of manipulative therapy, the forces used in normalizing areas of osteopathic lesion are (1) operator forces, (2) patient forces, (3) inherent or intrinsic forces, and (4) any combination of the above. Most of the time, a combination is used.

One type of operator force is a high velocity-low amplitude force (thrust) applied after re-

removal of all the slack and localization of the vectors of force at the particular point of joint motion restriction. The resultant motion overcomes the restriction.

Another type of operator force is one of low velocity-high amplitude, taking a joint through its full range of motion and thus stretching any tissues that may be contributing to limitation of motion. The more carefully the vectors of force are applied, the less force it takes to overcome the restriction and produce normal physiologic motion. Furthermore, the likelihood of producing trauma is reduced. In using patient forces, the operator has the patient assume a certain position and then directs him to contract certain muscles, or muscle groups, so as to produce motion at a particular point. This maneuver is often combined with operator forces to facilitate mobilization. In another technique using patient forces the patient inhales or exhales as the operator applies mobilization forces. Inhalation decreases the anteroposterior curves of the spine and externally rotates the extremities, while exhalation increases the anteroposterior curves of the spine and internally rotates the extremities. Many times these respiratory forces can be combined advantageously with operator forces.

In discussing the use of inherent forces, we must consider two different procedures. In one, the area of somatic dysfunction is placed in the position in which the dysfunction occurred with the resultant restricted joint motion. This procedure requires that the operator carefully test the ranges of motion, remembering that the affected joint will move in the direction which produced the injury more easily than in the direction of normalization. After holding the joint in the position of injury for 30 to 60 seconds, allowing time for tissue changes, the operator takes the joint back through the motion which produced the strain

or disability. The principle is the same as that used when Gunn's law is applied to treatment of a dislocated joint. The analogy of the kitchen door that swings both ways may help one understand this mechanism. If the door is pushed past a certain point it will stay open. One way to close the door is to push it a little farther open and let go of it; it will then swing back past "dead center" and close itself.

The other procedure using inherent force is sometimes spoken of as "functional technique." The operator, with a very delicate touch, places the joint in the position producing the least periarticular tension. A certain amount of splinting occurs in the tissues about any joint that is irritated, and if it can be positioned so that irritation is minimal, gradual resolution of the splinting will result and the joint will seek its normal physiologic position and motion. This technique requires delicate touch and is particularly applicable in acute joint strains from trauma and acute osteopathic lesions produced by a viscerosomatic reflex.

Because patient forces or inherent forces cannot be used under anesthesia to bring about normalization of a joint, one must depend entirely upon operator forces. These will, therefore, have to be of high velocity-low amplitude for breaking up adhesions, and of low velocity-high amplitude for stretching periarticular tissues. Most frequently the forces would be a combination of traction, rotation, and sidebending, with the velocity and amplitude selected for the problem at hand. The sidebending may be to either the same or the opposite side of the rotation, depending upon the mechanism involved in the production of the osteopathic lesion.

An understanding of the physiologic motions of the spine, as expressed by Fryette,¹² is helpful in determining exactly where motion is

restricted and what corrective forces are to be applied. To epitomize Fryette's interpretation, one can say that when the physiologic curves of the thoracic or lumbar spine are normal, or slightly increased, and sidebending is introduced, vertebral bodies rotate into the convexity. Whereas, if one decreases the anteroposterior curves of the thoracic or lumbar spine, the vertebral bodies rotate into the concavity. Where there is extreme backward bending or increase in the lumbar curve, the fifth lumbar vertebra may rotate into the concavity instead of the convexity.

The understanding of physiologic motion in the cervical spine is less clear; but, in general, whether one increases or decreases the physiologic curve of the cervical spine (produces flexion or extension), when sidebending is introduced the bodies of the second to sixth cervical vertebrae rotate into the concavity. The motion of the occiput on the atlas, and of the atlas on the axis, is separate and distinct because of the particular anatomy involved.

The type of osteopathic lesion associated with a decrease of the anteroposterior curve in the thoracic or lumbar area with a vertebral segment rotated into the concavity usually produces far more symptoms than are seen when the anteroposterior curves of the back are normal and sidebending is introduced, causing the bodies of the vertebra to rotate into the convexity. The reason is that the stress is usually localized at one particular set of intervertebral joints when a vertebra rotates into the concavity; whereas, when several vertebrae rotate into the convexity associated with a normal curve, or slightly increased curve, the stress is distributed over several segments.

Postoperative care

Postoperative care varies from operator to op-

erator. Some start ambulation and exercise early, having the patient up on his feet within 10 hours after the manipulative procedure. Others keep the patient in bed for 1 or 2 days, starting ambulation on the second or third day.

Many operators like to use traction, particularly after manipulating the back. Some use Buck's traction and others, pelvic traction. Buck's traction is used when the purpose of the primary procedure was to produce motion in the sacroiliac joints. Pelvic traction is used when the primary procedure was intended to produce normal motion in the lumbosacral area. In an effort to minimize the re-formation of adhesions, passive and active exercises are prescribed from two to four times a day. Some use radiation or induced heat and faradization, and others use hot moist packs.

Discussion

One of the major reasons for failure to accomplish adequate correction or mobilization of an area of osteopathic lesion is that the key restricted motion in the joint is one not under voluntary control. Joint motion not under voluntary control has to be evaluated very carefully in dealing with osteopathic lesions, as Mennell¹² points out. If manipulative therapy were used with this fact in mind, many patients would not have to be anesthetized for manipulative therapy. Some of the problems involving the elbow are probably most illustrative: One frequently finds that a patient who has pain around the head of the radius, or the wrist, or finds it difficult to pick up small objects or hold a cup of coffee, has had a strain at the elbow with a restriction of motion either in the abduction or adduction of the humero-ulnar joint (Figs. 1 and 2). When either of these motions is lost, the parallelogram motion between the radius and the ulna is lost, with

resulting discomfort at the head of the radius, weakness of the flexor muscles of the hand, and discomfort in the wrist.

After one checks the elbow, with a figure-of-eight motion, to determine exactly where the abduction or adduction restriction occurs, he can apply force directly through the restricted motion to re-establish normal abduction or adduction mobility. The radius can then be taken through its range of motion in relation to the ulna with relief of the pain at the head of the radius and at the wrist, and with restoration of normal function of the flexor muscles of the hand (Figs. 3 and 4).

Examples of motions in the cervical spine not under voluntary control which are susceptible to restriction are the lateral gliding of one cervical vertebra upon the other and the anteroposterior gliding motion. When one of these problems is found, motion can be normalized by sidebending rotation to the side of restriction with the cervical spine under moderate traction. It is very important that one apply traction along with the sidebending rotation. One should apply these forces through the joints parallel to the articular fac-

ets as he attempts to overcome the restriction in motion between two cervical vertebrae.

Low-back problems involving the lumbosacral joint or the fourth and fifth lumbar vertebrae can usually be handled without anesthesia providing there is adequate motion of the joints of the pelvis, namely, the symphysis pubis and the right and the left sacroiliac joints. It seems that the real problem occurs when the motion of one or both sacroiliac joints is markedly restricted, particularly if the sacrum is rotated on its right or left oblique axis.

For example, if the base of the sacrum is anterior on the right in relation to the posterosuperior spine of the ilium and rotated on its left oblique axis, one will find tenderness over the sacrotuberous ligament and over the superior sacroiliac ligaments on the left side. Since the fifth lumbar vertebra usually moves with the sacrum, its rotation to the right and sidebending to the left will be restricted. This type of osteopathic lesion, which frequently has to be treated under general anesthesia, is discussed by Soden.¹³ The pelvis is usually rotated to the same side as the anterior sacrum. One pro-



Fig. 1 (left). Abduction of the humero-ulnar joint. Fig. 2 (right). Adduction of the humero-ulnar joint.

cedure for mobilizing this area of lesion involves the participation of two operators. The patient is placed on the side of the anterior sacrum in a modified lateral Sim's position with arms hanging off the sides of the table, feet and knees together, and hips and knees flexed to about 90 degrees. While one operator holds the opposite shoulder down, the other operator, who is standing behind the patient and facing toward his head, reaches across and takes hold of the knees with his hand that is toward the patient's feet, placing the thenar eminence of his hand that is nearer the patient's head against the base of the sacrum near the upper part of the sacroiliac joint. He flexes and extends the hips until he feels the vectors of force directly under the thenar eminence that is against the sacrum (Fig. 5). He then slowly raises the knees and rotates the pelvis about a fulcrum created by his hand against the sacrum. He keeps applying the torsion force as long as there continues to be a release of tension and increased mobility throughout the pelvis and the spine. No quick movement is used and the procedure is stopped when no further tissue release is ob-

tained. At this point the hips and knees are slowly extended as the patient is rolled over into the prone position. The patient is then placed upon his back and the hips are taken through their full range of motion: flexion, extension, adduction, abduction, and internal and external rotation to stretch out the pelvic muscles and fascia.

A frequent low-back problem which may be seen with very acute symptoms is that of the patient who is bent over forward and then to one side to pick up an object. With this particular maneuver, the fifth lumbar vertebra rotates into the concavity and gets "caught" in the position, or there is a "bind," with the result that the patient cannot straighten up at all or can do so only partially. If, for example, a person leans over forward and sidebends to his right to pick up an object, there is forward bending at the lumbosacral area, rotation of L-5 to the right, and sidebending to the right. The degree of each component of this compound motion varies from patient to patient and also depends on whether or not there is any anomalous positioning of the articular facets. To treat this problem, the oper-

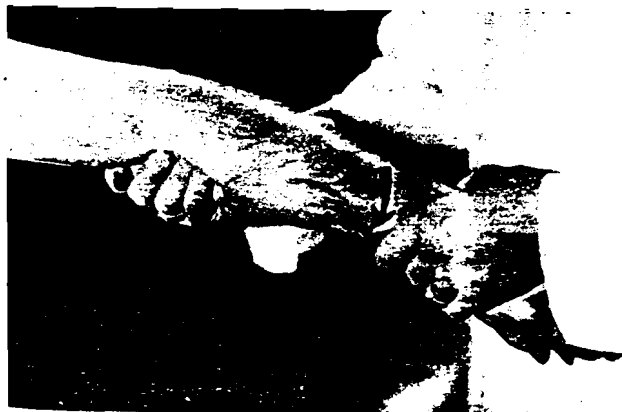

Fig. 3 (left). Pronation of the forearm with rotation of the radius about the ulna. Fig. 4 (right). Supination of the forearm with the radius becoming parallel to the ulna.



Fig. 5. The position of the hands of the two operators as one gets ready to rotate the pelvis to the right about the left oblique axis of the sacrum. Left, view from the back; right, view from the front.

ator places the patient in a modified left lateral Sim's position. The operator flexes and extends the knees and hips until the forces are localized at the lumbosacral junction. He produces sidebending to the left, rotation to the left, and backward bending of the spine at the lumbosacral junction. When all vectors of force are localized at the point where motion of L-5 is restricted, the operator applies a high velocity-low amplitude force to "free-up" the joint. Most of the time this type of osteopathic lesion or joint strain can be effectively treated by functional forces without anesthesia. Usually this can be done with little discomfort to the patient and minimal effort on the part of the operator.

Conclusions

Although my experience with manipulative therapy applied to the spine under general anesthesia is relatively recent, for quite some time I have felt that certain patients would have responded better and more quickly to




Fig. 6. The position of the patient for sidebending left, rotation left, and backward bending in the lumbosacral area.

manipulation if the procedure had been done under anesthesia. After reviewing the patients that I have treated under anesthesia, observing others doing manipulative procedures under anesthesia and reviewing their

records, and reading papers from Europe, Australia, and the United States by allopathic orthopedic surgeons, I believe that there is a definite place for manipulation under anesthesia. The procedure would definitely obviate the need for back surgery in many cases. However, I also believe that, because of a lack of skill, some physicians are manipulating the spine and appendages under anesthesia unnecessarily. Only physicians who are well trained in the art of manipulative therapy should employ anesthesia for such procedures.

Summary

Manipulative treatment of the spine and appendages under general anesthesia is considered as an elective modality whose success is directly related to the quality of the operator's manipulative skills. Disorders which respond well to manipulation under anesthesia are discussed, as are those which are contraindications to the procedure. Three reasons are given for some physicians' unfavorable attitude toward the procedure, and the importance of careful history-taking, thorough physical examination, and adequate laboratory and x-ray studies is emphasized, with a description of these diagnostic procedures. The preoperative preparation and the manipulative procedure itself are discussed, particular attention being given to the types of forces to be applied. A brief section on postoperative care is followed by conclusions based on the author's own experience and his observation of other operators and review of the pertinent osteopathic and allopathic literature.

The author acknowledges the help of many people in reviewing this subject, particularly Dr. Donald Siehl, Dayton, Ohio; Dr. Clifford Keating, Portland, Maine; Dr. Harold Clybourne, Columbus, Ohio; Dr. Hooker Tospon, St. Joseph, Missouri; and Dr. Paul Isaacson, Tucson, Arizona. The author also expresses appreciation to Dr. Harry Wright and Dr. Keith Buzzell, Kirksville, Missouri, for editorial help, and to Mr. Robert May, Kirksville, for the preparation of the illustrations.

1. Wiles, P., and Sweetnam, R.: *Essentials of orthopaedics*. Ed. 4. J. & A. Churchill Ltd., London, 1965
2. Tospon, H. N.: Personal communication
3. Siehl, D., and Bradford, W. G.: Manipulation of the low back under general anesthesia. *JAOA* 52:239-42, Dec 52
4. Siehl, D.: Manipulation of the spine under general anesthesia. *JAOA* 62:881-7, Jun 63
5. Siehl, D.: Personal communication
6. Mensor, M. C.: Non-operative treatment, including manipulation, for lumbar intervertebral disc syndrome. *J Bone Joint Surg* 37A:925-36, Oct 55
7. Mensor, M. C.: Non-operative treatment, including manipulation, for lumbar intervertebral-disc syndrome. *J Bone Joint Surg* 47A:1073-4, Jul 65
8. Burns, L., Chandler, L. C., and Rice, R. W., AOA Ed. Committee: Pathogenesis of visceral disease following vertebral lesions. American Osteopathic Association, Chicago, 1948
9. Rumney, I. C.: Structural diagnosis and manipulative therapy. *JAOA* 66:1261-61, Jul 67
10. Korr, I. M.: The neural basis of the osteopathic lesion. *JAOA* 47:191-8, Dec 47
11. Fryette, H. H.: *Principles of osteopathic technic*. Academy of Applied Osteopathy, Carmel, Calif., 1954
12. Mennell, J. McM.: *Back pain. Diagnosis and treatment using manipulative techniques*. Little, Brown and Co., Boston, 1960
13. Soden, C. H.: Manipulation of lower back under surgical anesthesia. In *Academy of Applied Osteopathy year book 1952. Selected osteopathic papers*. Academy of Applied Osteopathy, Carmel, Calif., 1952, pp. 31-5

Dr. Rumney, who is Ferrin T. Wilson Professor of Osteopathic Theory and Methods at Kirksville College of Osteopathy and Surgery, Kirksville, Missouri, was the recipient of a 1967-68 National Osteopathic Foundation fellowship grant through the co-operation of Smith, Kline & French Laboratories.

Dr. Rumney, Kirksville College of Osteopathy and Surgery, Kirksville, Missouri 63501.