

Manipulation Under Anesthesia: Pathomechanics

Chapter Author:
Robert S. Francis, D.C.

Associate Professor of Clinical Sciences
Course Director, Division of Post Graduate Studies
Texas Chiropractic College

Clinical Assistant Professor of Family Medicine
Department of Family Medicine
University of Texas Medical Branch at Galveston

Chief, Department of Chiropractic Medicine
Vista Medical Center Hospital

CRC Press copyrighted
2003

This chapter will develop an overview for a spinal manipulative model that identifies the manipulative lesion for which MUA is most effective – the treatment of pathomechanics of the spine. This discussion conveys the role of the various factors comprising this model which include the three joint complex (intervertebral disc and two posterior motor units), resting length of musculature, articular neurology, the pressure hierarchy of the intervertebral foramen and the role of synovial production and cavitation.

These factors play an important role in moderating the source of back pain by restoring, improving and maintaining mechanical integrity.

It has been well documented in the medical literature that chronic unresolved musculoskeletal conditions respond well to manipulation under anesthesia. MUA is a procedure designed to restore the lost range of motion, flexibility and visco-elasticity of the spine and extremities and to reduce scar tissue in soft tissues, peri and intra articular structures which results in articular dyskinesia.

The restoration of motion and the reduction of scar tissue results in more flexibility and visco-elasticity of the paraspinal musculature and associated articulations thereby increasing the functional capacity of the patient.

MUA is a procedure utilized in a selected patient population which has been recalcitrant to an adequate trial of conservative care in the office setting. MUA requires the use of non-paralyzing anesthesia (patients continue to breath on their own during the procedure) towards an effort to provide relaxed skeletal musculature enabling the manipulator to reduce fibroblastic proliferative tissue and restore

restore articular motion without patient guarding and pain. Generally, pre-op medications include Versed and Fentanyl with Propofol used in the Operating Room without intubation to accomplish flaccid muscular relaxation.

This procedure is an out patient procedure and is performed in an appropriate setting providing access to monitoring and resuscitation equipment in a facility certified or licensed to provide a safe operative environment which can provide transfer capability to inpatient care.

Spinal Manipulative Therapy is designed to restore biomechanical integrity to areas of articular dyskinesia due to pathomechanical factors including loss of joint mobility, fibroblastic proliferative changes of the supporting soft tissues resulting in decreased or lost flexibility/visco-elasticity and neurological and vascular changes resulting from articular dyskinesia.

The Source of Back Pain



Not all back pain is necessarily due to disorders of the spine. Lumbar pain can be due to visceral or vascular disease in the abdomen or pelvis. Therefore, the assessment of lumbar pain must include an assessment of these possibilities. It is not the scope of this text to address a review of systems other than the pathomechanical systems which become the treatment objective of the MUA procedure.

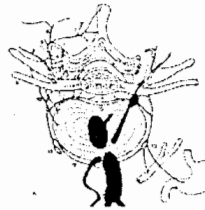
There are two types of pain based on physiological considerations- somatic and radicular. Somatic pain stems directly from musculoskeletal structures of the lumbar spine. Radicular pain is caused by disorder of the spinal nerves or the spinal nerve roots.

Any structure that has a nerve supply is a source of pain. The structures in the lumbar spine that receive a nerve supply include the zygapophyseal joints, the ligaments of the posterior elements, the paravertebral muscles, the dura mater, the anterior and posterior longitudinal ligaments and the intervertebral discs.

Kellgren demonstrated that low back pain could be induced by stimulation of the lumbar back muscles and interspinous ligaments. Steindler and Luck showed that certain forms of low back pain could be relieved, at least temporarily, by anesthetizing these same structures. It has been experimentally shown that stimulation of lumbar zygapophyseal joints could cause low back pain in normal volunteers and that back pain stemming from these joints could be relieved by fluoroscopically controlled blocks of their nerve supply. It has also been demonstrated experimentally with provocation discography that intervertebral discs can be a source of pain. The dura mater has also been shown to be able to cause back pain with experiments demonstrating the dura mater/back pain relationship. Back pain was evoked by traction on the dural sleeves of lumbar nerves by pulling on sutures threaded through the dura at operation for laminectomy and in another experiment, chemical irritation of the dura, in the form of injections of hypertonic saline, evoked back pain. All innervated structures of the back except the blood vessels have been shown experimentally to be capable of producing back pain.

➤ However, distension of epidural veins is thought to cause pain as we will see in the discussion of vascular considerations in the chapter.

Articular Neurology



We will use the lumbar spine in this chapter as a model to illustrate these mechanisms. It is the medial branch of the dorsal primary ramus that is of paramount clinical relevance due to its distribution to the zygapophyseal joints. The medial branches of the dorsal rami run across the top of their respective transverse processes and pierce the dorsal layers of the intertransverse ligament at the base of the transverse process. Each medial branch supplies the zygapophyseal joint above and below its course. Each zygapophyseal joint receives an additional innervation ventrally, from the dorsal ramus in front of the joint. Each joint therefore receives a multiple innervation: from a dorsal ramus and two medial branches.

To achieve reduction in symptoms and decrease in pain, manipulation is utilized to recruit the neurological mechanism of collateral inhibition. Collateral inhibition is

that part of the arthrokinetic reflex that inhibits the central transmission of pain through mechanoreceptor collateral fibers inhibiting the nociceptors in the posterior motor units of the spine and the zygapophyseal capsules.

The muscular distribution of the medial branches of the lumbar dorsal rami is very specific. Each medial branch supplies only those muscles that arise from the lamina and spinous process of the vertebra with the same segment as the nerve. Therefore, the muscles arising from the spinous process and lamina of a vertebra are innervated by the medial branch of the dorsal ramus that issues immediately below that vertebra. This relationship indicates that the principal muscles that move a particular segment are innervated by the nerve of that segment. Oftentimes, diagnostic facet blocks, selective nerve root blocks and facet challenges confirm segmental arthrogenic etiology for paravertebral muscles spasms.

The mechanoreceptors include kinesioreceptors, baroreceptors, and proprioceptors. As long as the mechanoreceptors' sensory input to the cord is within normal limits, a collateral fiber from each mechanoreceptor inhibits nociception and the central transmission of pain.

However when, for example, there is abnormal range of motion of the posterior motor units, kinesioreception (sensory input regarding normal or aberrant range of motion) is abnormal, the collateral fiber inhibiting nociception from the kinesioreceptor no longer inhibits the nociception. The threshold for depolarization of the nociceptor is thereby lessened requiring fewer stimuli to depolarize the nociceptor causing pain.

If additional stimulation of abnormal sensory input occurs such as a decrease in synovial fluid production due to lack of proper motion of the joint, the intra-articular pressure changes and the barroreceptor collateral inhibition is interrupted thereby causing an even more sensitive state of depolarization of the nociceptor.

If this condition persists, the lack of synovial fluid production due to lack of motion causes a settling or imbrication of the facets due to decreased intra-articular distention and development of intra-articular microadhesions. The proprioceptor collateral inhibition is interrupted due to abnormal stimulus from the orientation in space of the facets. With all three mechanoreceptors ceasing collateral inhibition of nociception, this thereby fully initiates the arthrokinetic reflex causing a cascade of nociception resulting in a motor response to the segmental level from which the stimulus originated.

LSTT

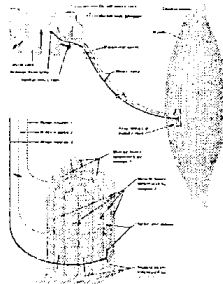
The nociceptor input is through the lateral spinothalamic tract, which carries pain and temperature. When fully depolarized, the nociceptor initiates an arthrokinetic reflex resulting in a state of hypertonic paraspinal muscle splinting and pain.

Manipulation restores the mechanical integrity of the joint by increasing range of motion and disrupting micro-adhesions thereby restoring kinesioreception and its collateral inhibition to nociception. This restoration of motion allows for increased stimulus to the synovial membrane which produces synovial fluid in direct proportion to the mechanical stimulation it receives from motion of the joint which in turn produces more synovial fluid and exchanges existing fluid in the joint. The barroreceptor in the joint senses increased pressure from intra-articular fluid and restores its corresponding collateral inhibition thereby inhibiting the central

transmission of pain through the nociceptors resulting in a state of relative muscular relaxation.

Additional stimuli can initiate nociception such as chemical noxious stimuli. With chronic low grade inflammatory conditions, an inflammatory “soup” is created replete with substance P, bradykinins, and prostaglandins causing irritation to nociceptors initiating the arthrokinetic reflex resulting in a state of hypertonicity of the segmental muscles. Chronic inflammation allows for microphage and fibroblast migration to the site which further complicates the clinical sequelae. Proper motion of the joints allows for fluid exchange and nutrition to the joints which prevents the accumulation of inflammatory noci-irritant mediators and fibroblastic substances. Proper motion restores the mechanoreceptor mechanism of collateral inhibition of pain. It is the mechanical input to the joint that is responsible for restoration of collateral inhibition, reduction of microadhesions and the pain-free state.

Proprioceptive Neuro Facilitation



Chronic pathomechanics is often accompanied by chronic muscular contractions or shortening which further contributes to articular dyskinesia. It is essential to address the soft tissue component of articular dyskinesia for complete restoration of

the pathomechanical lesion. A shortened musculature crossing the joint creates compressive forces across the joint further compromising joint mechanics and contributing to the articular dyskinesia.

A longer resting length of the musculature often results post SMT. This is accomplished through the process of proprioceptiveneurofacilitation (PNF). This occurs when the spindle cell mechanism in the belly of the muscle is stimulated to reset to a new resting length after the actin/myosin heads are gently stretched or pulled apart under anesthesia.

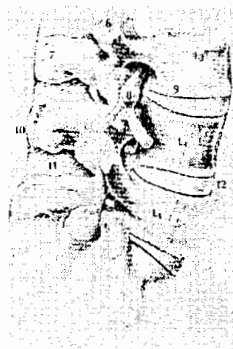While asleep, the sensory and motor mechanisms of the skeletal muscles are “turned off”. The muscles are stretched to a new and longer resting length. Once awakened, this system is “turned back on” and the messages sent by the golgi tendon organ and received by the spindle cell is different than before the stretch resulting in a longer resting length pursuant to the PNF effect. Proprioceptiveneurofacilitative of the golgi tendon organ and the spindle cell result is less tonic muscle contraction reducing compressive forces across joints. Microadhesions present in the myofibrils contributing to contractures and decreased elasticity are also reduced by this stretching resulting in a more visco-elastic, flexible and functional musculature.

Benefits of MUA procedures include the reduction of peri/intra-articular microadhesions in and about the posterior motor units, restoration of the pathomechanics in the three-joint complex (two posterior motor units and the intervertebral disc joint), increase in range of motion, flexibility and visco-elasticity of the soft tissues, a reduction of fibroblastic proliferation, and recruitment of collateral inhibition thereby preventing pain.

The pain picture consists of biochemical and mechanical components. By only addressing the chemical component, for example administering anti-inflammatory medications or epidural or facet injections, only one factor of pain production is addressed – the biochemical. Restoring mechanical integrity to the joint as well as biochemical components with manipulation provides more comprehensive healing by establishing proper mechanics of the joint allowing for the exchange of fluid and the restoration of appropriate biochemical balance. These synovial fluid dynamics were well documented by Robert Salter, M.D. in several landmark experimental studies demonstrating that fluid exchange and joint nutrition is dependent upon proper motion of the synovial joint and that lack of proper motion accelerates degenerative changes. Salter showed that synovial joints produce synovial fluid directly proportionate to the amount mechanical stimulation the synovial membrane receives through joint motion.

The cause of inflammation is commonly articular dyskinesia of the joint and is therefore the source of altered chemistry. By addressing the pathomechanical source with MUA, total restoration of joint dynamics can be established. The manipulative results may also be enhanced with proper and judicious administration of injections.

Pressure Hierarchy of the Intervertebral Foramen



The IVF transmits significant structures which must maintain a defined pressure hierarchy to function normally. These include the artery, capillaries, vein, fascicles of the spinal nerve, and all are cushioned with adipose and connective tissue inside the IVF tunnel. The nerve roots are particularly susceptible to the consequences of vascular compression, particularly venous compression, because they lack lymphatics. Consequently, there are no alternative channels whereby exudated fluid can leave the roots. Intraneural and perineural edema can interfere with nerve conduction by exerting pressure on axons. Nerve root ischemia can be the result of long standing edema or inflammatory exudate which tends to organize, that is, convert to fibrous tissue.

This system of maintaining the pressure hierarchy of the intervertebral foramen is described as follows:

$$(P_a > P_c > P_v > P_f > P_t)$$

meaning the pressure in the artery must be greater than the pressure in the capillary which must be greater than the pressure in the vein which must be greater than the intrafascicular pressure of the spinal nerve which finally in turn must be greater than the pressure of the 'tunnel' or IVF itself.

The interstitial fluid inside the fascicle (endoneural fluid pressure) is greater than that of the surrounding tissues. The intrafascicular vascular bed extends along the whole length of the nerve and consists mainly of capillaries that communicate with the extrafascicular vessels through multiple anastomoses. When there is a pressure change at the IVF, for example from decreased disc height, it affects first and most

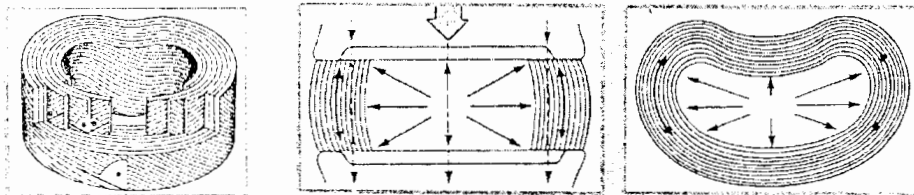
significantly the most distensible tissue in this system which is the venous system. Due to its thinner vascular wall, the veins are more easily compressed than are the arteries and capillaries. Data obtained from studies of nerve roots subjected to graded, acute compression demonstrate that even low-pressure compression of the nerve roots (5-10 mm Hg) can induce venous congestion in the intraneural microcirculation and up to 130 mmHg compression results in complete ischemia of the nerve root. Intraneural edema results in extravasation of serum albumin even at 50 mm Hg. It has been shown that mechanical compression of nerve roots produces acute and chronic impairment of the blood supply and transport of nutrients to the nerve tissue. As a result of mechanical compression, waste product clearance from the nerve root tissue is also impaired. These alterations of the metabolic balance potentiates chronic tissue changes such as fibroblastic proliferation in and around the nerve root which can result in clinical manifestations of epineural fibrosis. Clinically, epineural fibrosis may mimic discogenic radicular pain due to the tethering of the existing nerve root causing distinct dermatomal distribution of pain patterns. MUA can effectively reduce this scar tissue with the inclusion of specific fibrosis release procedures (FRP). The specific MUA stretching techniques of FRP is described elsewhere in this text and can be referred to in order to further enhance the understanding of epineural scar tissue reduction.

In summary, disturbance of the IVF pressure hierarchy can induce changes in microcirculation and nutrition of the nerve root. The permeability of the vasculature is increased resulting in endoneural edema which increases endoneural fluid pressure and migration of inflammatory mediators to the area stimulated by

the extravasation of serum albumin leading to a low grade chronic inflammatory process of fibroblastic proliferation in and about the nerve root.

It is this fibroblastic proliferation, if allowed to persist, which alters the normal neuro-mechanics of the spine manifesting clinically as articular dyskinesia or aberrant spine pathomechanics.

The Intervertebral Disc



Anatomically, the IVD consists of two parts, the annulus fibrosus and the nucleus pulposus. The annulus is distinct at its periphery and the nucleus is quite distinct at the center, however, there is no clear boundary between the nucleus and the annulus within the disc. The major components of the disc are proteoglycans and collagen with proteoglycan content greater in the nucleus and collagen content greater in the annulus.

The nucleus is made up of glycosaminoglycans which when linked together in long chains become proteoglycans which physiochemically have the property of attracting and retaining water, a process called water imbibition. A normal healthy well hydrated disc has a water imbibition ratio of 9:1. With aging and dessication this ratio, so essential to the mechanical integrity of the IVD, decreases resulting in decreased ability of the nucleus to attract and retain water allowing for less deformation. It is this water imbibition property that gives the nucleus its viscoelasticity.

Biomechanically, the fluid character of the nucleus allows for deformation under pressure but its volume cannot be compressed. When compressed, its fluid nature will deform transmitting pressure in all directions like a balloon filled with water. Any change in the proteoglycan, and thereby water, content of the nucleus will inevitably alter the mechanical properties of the disc because the water content of the nucleus is a function of its proteoglycan content.

The annulus consists of collagen fibers arranged in 10-12 sheets of concentric rings called lamellae surrounding the nucleus. The fibers run alternately at about 65° angle to the vertical in successive layers such that one lamella is oriented 65° to the right and the next layer 65° to the left.

The annulus is much like a thick book such as a phone directory. When the book is folded into a cylindrical shape and stood on end, its weight bearing capacity is significant so long as the pages do not bend or buckle. However, sustained pressure would buckle this system without the nucleus providing its internal turgor due its water content exerting pressure in all directions, 360° spherically, like a water balloon. So with the phone book on end and a competent water balloon inside, this system can sustain tremendous axial loading as the nucleus supports the annulus. Prolonged axial loading, however, will tend to reduce the height of the nucleus as it loses water content due to constant axial loading. Intermittent pressure allows the nucleus to re-imbibe water as pressure is alternately increased and decreased. With axial loading, the nucleus begins to deform the annulus, it tries to expand radially which stretches the lamellae outwards. The tensile properties of the annular collagen resist the stretch and oppose the outward pressure.

This is much like a woven wicker toy, the Chinese finger trap, which is made up of alternating wicker fibers in which once your fingers are inserted tip to tip and attempts made to pull them apart the fibers tighten. If the fingers, while pulling apart, are twisted inside, the alternating wicker fibers tighten even further around the fingers containing them tightly inside the 'annulus' of the toy. So functions the annulus under traction and torsion. It tightens around the nucleus opposing radial pressure of the nucleus causing the nuclear pressure to increase and exert upward and downwards pressure separating the vertebra above from the one below further causing the lamella to tighten its concentric alternating rings of lamella as it is pulled from above and below just as the finger trap toy does around the finger trapped inside when attempts are made to pull the fingers out.

This very mechanism is recruited during manipulation to reduce disc protrusions and herniations. This is the mechanism alluded to by James Cyriax, M.D. who reported in his *Illustrated Manual of Orthopedics* that "*the main purpose of manipulation is restoration of internal derangement of the disc.*"

There have been many studies on intra-discal pressure demonstrating different postures and the concomitant pressure increases and decreases in the nucleus with the different postures. Essentially, axial loading in the standing, sitting or forward bending positions increase intra-discal pressure while recumbent side lying or supine positions decrease intra-discal pressure. Nuclear pressure decreases directly as a result of decreased axial loading or compression. These pressures can change from as much as 140 psi at the L5 nucleus in the seated position to as little as 25 psi at the L5 nucleus in the supine position so that the lateral decubitus position used

for lumbar manipulation prior to the thrust procedure is actually a decompressive procedure. Then adding the traction and torsional effects of the annulus during manipulation combined with the decreased nuclear pressure from the position of the patient, there is intra-discal pressure reduction at the nucleus allowing water to enter the disc through its inherent imbibition property. This in turn follows the mechanism described above as the two functional units of the intervertebral disc support each other with hydration and tensile properties of visco-elasticity resulting in a more functional intervertebral disc.

Cavitation



An audible “pop” often accompanies spinal manipulation. This is the process of cavitation. Cavitation ($PV=nrt$) occurs when the intra-articular pressure decreases. Volume and pressure are inversely proportionate. During SMT, the joint surfaces are separated increasing the volume of the joint space and reducing the intra articular pressure. The reduction in pressure causes a CO_2 gas bubble to come out of the synovial fluid. This causes the audible “pop” much the same as removing the

bottle cap from soda pop which reduces the pressure inside the bottle and CO₂ comes out of solution making a popping noise.

This cavitation has been experimentally shown to increase joint space post manipulation as the gas bubble distends the joint a slight degree. This distention, or internal auto-traction, may be sufficient to reduce the pressure at the IVF which can cause venous congestion and the clinical sequelae that manifest from chronic compression and inflammation at the IVF.

With even minimal facet distention, a reduction in intra discal pressure is accomplished. As the water imbibition properties of the nucleus imbibe water it allows the nucleus and annulus to function with greater integrity as mentioned above. Salter's landmark work on synovial fluid production and exchange demonstrates the mechanism responsible for the facet joint dynamics seen in manipulation. The stimulation of the synovial membrane through manipulation allows simultaneous production and exchange of synovial fluid maintaining and restoring the intra-articular pressure and fluid dynamics affecting collateral inhibition preventing nociceptive depolarization as described by articular neurology section herein.

Arthrogenic conditions and their attendant myofascial symptoms are among the most common treated with MUA. This can be a confounding presentation to the provider unfamiliar with facet syndrome. Facet syndrome is common but because it is not demonstrable on plain film radiographic studies, it is frequently misdiagnosed as nerve compression syndromes, dismissed as myofascial pain or, unfortunately, simply overlooked. It is known that this syndrome may produce pain in the legs and

the course of this referred pain may be in the buttocks, lateral or posterior thigh down to the knee and occasionally outer calf but rarely to the foot.

The differential diagnosis of discogenic versus arthrogenic pain is necessary to rule out space occupying lesions. In the absence of space occupying lesions there may persist nerve root tension signs. This is almost always due to epineural fibrosis tethering the existing nerve root as described above. It is most effectively treated with a judicious combination of epidural steroid injection and MUA-FRP procedures. The innervation of the facet joints has been adequately described above. The mechanical intervention of MUA procedures in facet syndrome recruits those mechanoreceptor mechanisms responsible for collateral inhibition and the decreased input of the central transmission of pain while at the same time restoring the mechanical integrity of the posterior and intervertebral joints – the three joint complex.

The restoration of intervertebral disc integrity by restoring the water imbibition ability of the nucleus pulposus is accomplished by the decreased intra-discal pressure accompanying the manipulation. The slight distention of the joints due to cavitation and the gas bubble occupying more space inside the joint effectively ‘tractions’ the vertebra for about $\frac{1}{2}$ millimeter as demonstrated by Sandoz. This allows for imbibition of water into the nucleus from the adjacent vertebral bodies allowing it to distend and reinforce the annulus fibrosis as described above. The two functional units of the intervertebral disc, the nucleus and the annulus, are then allowed to function as a unit to provide the visco-elasticity and tensile properties necessary to the competent disc.

The appropriate functioning of three joint complex is necessary to maintain the pressure hierarchy of the intervertebral foramen (IVF). The pressure hierarchy of the IVF prevents the venous congestion at the site of the existing nerve root thereby disallowing accumulation of the inflammatory edematous 'soup' constituents responsible for epineural fibrosis and mimicking nerve root tension signs of a space occupying lesion.

Manipulation Under Anesthesia has a definite place in the clinical armamentarium of the physical medicine practitioner. The basic science studies herein described and the clinical application of that information provides an enduring status for MUA procedures in the broad spectrum of clinical interventions for chronic pain patients.

References

- Bogduk N and Engel RM. The menisci of the Lumbar Zygapophyseal Joints. *J Anat* 1982; 135:795-809.
- Bogduk N, Jull G 1985 The theoretical pathology of acute locked back: a basis for manipulative therapy. *Manual Medicine* 1: 78-82
- Chen HI, Granger HJ and Taylor AE 1976 Interaction of capillary, interstitial and lymphatic forces. *Circ Res* 39: 245-254.
- Cyriax J. 1983 *Textbook of orthopaedic medicine*, Vol. 1, 8th ed. London: Bailliere Tindall
- Dorman. T 1991 *Diagnosis and Injections Techniques in Orthopedic Medicine*. Williams & Wilkins Baltimore
- Engel R, Bogduk N 1982 The menisci of the lumbar zygapophyseal joints. *J Anat* 135: 795-809
- Francis R. 1992 Guidelines for Chiropractic Quality Assurance and Practice Parameters: Proceedings of the Mercy Center Conference, commission member, Aspen Publishers.

- Francis R. 1989 Spinal manipulation under general anesthesia: a chiropractic approach in a hospital setting. *ACA J Chiropr* Dec;12:39-41.
- Francis R, Beckett RH. 1994 Spinal manipulation under anesthesia. *Adv Chiropr* Mosby Publishers Vol.1:325-40.
- Francis R. 1995 Spinal manipulation under anesthesia: a review of chiropractic training programs and protocols. *Am Chiropr* Sep-Oct;27, 37.
- Francis R. 1991 Manipulation under anesthesia. *Am Chiropr* Dec;24, 26-7.
- Francis R. 2002 Postgraduate & continuing education courses: September. Pasadena (TX): Texas Chiropractic College; [cited 2002 Oct 01]. [5 p].
- Giles, LGF. Lumbosacral zygapophyseal joint inclusions. *Manual Med* 1986;2: 89-92.
- Giles LGF and Taylor JR. Innervation of human lumbar zygapophyseal joint synovial folds. *Acta Orthopaedica Scand* 1987(b);58:43-46.
- Giles LGF, Taylor JR 1982 Inter-articular synovial protrusions. *Bull Hosp Joint Dis* 42: 248-255.
- Gordon R, Rogers R, West D, Matthews R and Miller R. 2002 Manipulation under Anesthesia: An Anthology of Past, Present and Future Use. In: Pain Management, A Practical Guide for Clinicians 6th Ed. Weiner R, editor, CRC Press, New York.
- Haldeman S. The neurophysiology of spinal pain syndromes. In Haldeman S, ed. *Modern Development in the Principles of Chiropractic*. New York: Appelton-Century Crofts; 1980:119-142.
- Kellgren JH 1939 On the distribution of pain arising from deep somatic structures with charts of segmental pain areas. *Clin Sci* 4: 35-46.
- Korkala O, Gronblad M, Liesi P, Karaharju E 1985 Immunohistochemical demonstration of nociceptors in the ligamentous structures of the lumbar spine *Spine* 10: 156-157
- Kramer J, Kolditz D, Gowin R 1985 Water and electrolyte content of human intervertebral disc under variable load. *Spine* 19: 69-71
- Low P, Marchand G, Knox F and Dyck PJ. 1977 Measurement of endoneurial fluid pressure with polyethylene matrix capsules. *Brain Res* 122:373-377.
- Murphy, RW 1977 Nerve roots and spinal nerves in degenerative disk disease. *Clin Orthop* 129: 46-60

Myers RR, Murakami H and Powell HC. 1986 Reduced nerve blood flow in edematous neuropathies – a biochemical mechanism. *Microvasc Res* 32: 145-151.

Olmarker K, Rydevik B, Holm S. 1989 Edema formation in spinal nerve roots induced by graded, experimental compression. An experimental study on the pig cauda equina. *Spine* 14: 569-573.

Olmarker K, Rydevik B, Hansson T and Holm S. 1990 Compression-induced changes of the nutritional supply to the porcine cauda equina. *J Spinal Disord* 3:25-29.

Pedersen HE, Blunck CFJ, Gardner E 1956 The anatomy of lumbosacral posterior rami and meningeal branches of spinal nerves: with an experimental study of their function, *J Bone Joint Surg* 38A: 377-391

Rydevik B and Norborg C 1980 Changes in nerve function and nerve fibre structure induced by acute, graded compression. *J Neurol Neurosurg Psychiatry* 43: 1070-1082.

Steindler A, Luck JV 1938 Differential diagnosis of pain low in the back: allocation of the source of pain by the procaine hydrochloride method. *JAMA* 110: 106-112

Sunderland, S *Nerves and Nerve Injuries*. 1978 2nd ed. Edinburg/London/New York: Churchill Livingstone.

Sunderland S. 1976 The nerve lesion in the carpal tunnel syndrome. *J. Neurol Neurosurg Psychiatry* 39: 615-626.

Taylor JR, Twomey LT 1979 Innervation of the lumbar intervertebral discs *Med J Aust* 2: 701-702

Urban J, Maroudas A 1980 The chemistry of the intervertebral disc in relation to its physiological function. *Clin Rheum Dis* 6: 51-76

White AA, Panjabi MM 1998 *Clinical Biomechanics of the Spine*. Lippincott, Philadelphia.

Wiberg G 1947 Back pain in relation to the nerve supply of the intervertebral disc. *Acta Orthop Scandinav* 19: 211-221

Wyke B 1980 The neurology of low back pain. In: Jayson MIV (ed) *The lumbar spine and back pain*, 2nd ed. Pitman, Tunbridge Wells, Ch 11, p 265-339.

Yoshizawa H, O'Brien JP, Thomas-Smith w, Trumper M 1980 The neuropathology of intervertebral discs removed for low back pain. *J Path* 132: 95-104.